

Differentiating Immunoglobulin G4-Related Sclerosing Cholangitis from Hilar Cholangiocarcinoma

Taku Tabata*, Terumi Kamisawa*, Seiichi Hara*, Sawako Kuruma*, Kazuro Chiba*, Go Kuwata*, Takashi Fujiwara*, Hideto Egashira*, Koichi Koizumi*, Junko Fujiwara†, Takeo Arakawa†, Kumiko Momma†, Masanao Kurata‡, Goro Honda‡, Koji Tsuruta‡, and Takao Itoi§

Departments of *Internal Medicine, †Endoscopy, ‡Surgery, Tokyo Metropolitan Komagome Hospital, and §Department of Gastroenterology and Hepatology, Tokyo Medical University, Tokyo, Japan

Background/Aims: Few studies have differentiated immunoglobulin G (IgG) 4-related sclerosing cholangitis (IgG4-SC) from hilar cholangiocarcinoma (CC). Thus, we sought to investigate useful features for differentiating IgG4-SC from hilar CC. **Methods:** We retrospectively compared clinical, serological, imaging, and histological features of six patients with IgG4-SC and 42 patients with hilar CC. **Results:** In patients with hilar CC, obstructive jaundice was more frequent ($p < 0.01$), serum total bilirubin levels were significantly higher ($p < 0.05$), serum CA19-9 levels were significantly higher ($p < 0.01$), and serum duke pancreatic monoclonal antigen type 2 levels were frequently elevated ($p < 0.05$). However, in patients with IgG4-SC, the serum IgG ($p < 0.05$) and IgG4 ($p < 0.01$) levels were significantly higher and frequently elevated. The pancreas was enlarged in all IgG4-SC patients but only in 17% of hilar CC patients ($p < 0.01$). Salivary and/or lacrimal gland swelling was detected in only 50% of IgG4-SC patients ($p < 0.01$). Endoscopic retrograde cholangiography revealed that the hilar or hepatic duct was completely obstructed in 83% of hilar CC patients ($p < 0.01$). Lower bile duct stenosis, apart from hilar bile duct stenosis, was more frequent in IgG4-SC patients ($p < 0.01$). Bile duct wall thickening in areas without stenosis was more frequent in IgG4-SC patients ($p < 0.01$). **Conclusions:** An integrated diagnostic approach based on clinical, serological, imaging, and histological findings is necessary to differentiate IgG4-SC from hilar CC. (*Gut Liver* 2013;7:234-238)

Key Words: Immunoglobulin G; IgG4-related sclerosing cholangitis; Hilar cholangiocarcinoma; Endoscopic retrograde cholangiopancreatography

INTRODUCTION

Immunoglobulin G (IgG) 4-related disease is a unique systemic inflammatory disease characterized by tumorous swelling of affected organs and elevation of serum IgG4 levels.^{1,2} Auto-immune pancreatitis (AIP) is a prototype of IgG4-related disease.² In some cases, only one organ is clinically involved, while in others, several organs are affected.² IgG4-related sclerosing cholangitis (IgG4-SC) is a biliary manifestation of this systemic disease. The histological basis is transmural fibrosis, with abundant infiltration of IgG4-positive plasma cells and lymphocytes and obliterative phlebitis.¹⁻⁵

Stenosis of the lower bile duct is seen frequently in AIP, which should be differentiated from pancreatic head cancer. When stenosis develops in the hilar or intrahepatic bile duct, the cholangiographic appearance is similar to that of primary sclerosing cholangitis (PSC) or hilar cholangiocarcinoma (CC).¹⁻⁵ Although there have been some reports on the differences between IgG4-SC and PSC,^{3,4,6} there are few studies on differentiating IgG4-SC from hilar CC.^{3,7-9} IgG4-SC is particularly difficult to differentiate from hilar CC when it is not associated with AIP, or when the diagnosis of AIP is unclear.¹⁰ Because IgG4-SC responds well to steroids, but a diagnosis of hilar CC leads to hepatectomy, accurate differentiation between IgG4-SC and hilar CC is essential. However, contemporary diagnostic modalities cannot reliably differentiate the two diseases. This study is aimed to clarify the differences in clinical, serological, imaging, and histological findings between IgG4-SC with stenosis of the hilar bile duct and hilar CC.

Correspondence to: Terumi Kamisawa

Department of Internal Medicine, Tokyo Metropolitan Komagome Hospital, 3-18-22 Honkomagome, Bunkyo, Tokyo 113-8677, Japan
Tel: +81-3-3823-2101, Fax: +81-3-3824-1552, E-mail: kamisawa@cick.jp

Received on May 23, 2012. Revised on June 20, 2012. Accepted on July 2, 2012. Published online on February 7, 2013.

pISSN 1976-2283 eISSN 2005-1212 <http://dx.doi.org/10.5009/gnl.2013.7.2.234>

© This is an Open Access article distributed under the terms of the Creative Commons Attribution Non-Commercial License (<http://creativecommons.org/licenses/by-nc/3.0>) which permits unrestricted non-commercial use, distribution, and reproduction in any medium, provided the original work is properly cited.

MATERIALS AND METHODS

1. Study patients

A total of six patients (five men and one woman; median age, 71 years; range, 52 to 76 years) with IgG4-SC and 42 patients with hilar CC (23 men and 19 women; median age, 74 years; range, 52 to 89 years) diagnosed from 2000 to 2010 were enrolled in this study. All of the IgG4-SC patients fulfilled the following three criteria: 1) biliary strictures at the hilar bile duct; 2) association with type 1 AIP diagnosed according to the International Consensus Diagnostic Criteria of AIP;¹¹ and 3) steroid responsiveness. The six patients were followed up for a duration of 2 to 11 years (average, 7.8 years), and any diagnosis of cancer was ruled out during their clinical course. The patients with hilar CC were diagnosed through radiological, histological and/or cytological modalities, and their disease followed the typical clinical course. This study was approved by the Institutional Review Board of Tokyo Metropolitan Komagome Hospital, and informed consent for all invasive procedures was obtained from all patients.

2. Clinical, laboratory, and imaging analysis

Age at time of diagnosis, sex, initial symptoms such as obstructive jaundice and abdominal pain, serum total bilirubin, serum tumor markers (CA19-9, carcinoembryonic antigen, duke pancreatic monoclonal antigen type 2 [DUPAN-2]), serum IgG, IgG4 and IgE levels, and autoantibodies (antinuclear antigen and rheumatoid factor) were abstracted from the clinical records. Serum IgG4 levels were measured by nephelometry using IgG subclass kits. A cutoff value of 135 mg/dL, which is widely accepted, was used.

Computer tomography (CT), ultrasonography (US), magnetic resonance imaging (MRI), and magnetic resonance cholangiopancreatography (MRCP) were conducted in all patients. Endoscopic retrograde cholangiopancreatography (ERCP) was performed in six IgG4-SC patients and in 18 patients with hilar CC. Percutaneous transhepatic biliary drainage was performed in 28 patients with hilar CC. Intraductal ultrasonography (IDUS) was performed in four IgG4-SC patients. Endoscopic transpapillary bile duct biopsy and cytological examination were performed in five and six IgG4-SC patients, and in one and 28 hilar CC patients, respectively. Imaging findings were assessed as follows: enlargement of the pancreas via CT and MRI; abdominal lymph node swelling via CT; length of stenosis of the hilar bile duct via ERCP and/or MRCP and/or percutaneous transhepatic cholangiography; delineation of stenotic bile duct via ERCP; and thickening of bile duct wall in areas without bile duct stenosis and gallbladder wall via CT and/or US and/or IDUS. Swelling of the salivary and/or lacrimal glands was evaluated clinically and/or via CT. The definition of pancreatic enlargement was based on definition of Haaga *et al.*¹²

3. Statistical analysis

The differences between the two groups were analyzed using Fisher's exact test or the Mann-Whitney U test. In all tests, corrected p-values of less than 0.05 were considered statistically significant.

RESULTS

1. Clinical and serological differences

Both diseases occurred predominantly in elderly males. As the initial symptom, obstructive jaundice occurred more frequently in patients with hilar CC (IgG4-SC vs hilar CC, 16% vs 76%; $p < 0.01$). Obstructive jaundice fluctuated during the course of two of the IgG4-SC patients. The median serum total bilirubin levels were significantly higher in the patients with hilar CC (0.7 mg/dL vs 3.8 mg/dL, $p < 0.05$). In comparing tumor markers between IgG4-SC patients and hilar CC patients, the serum CA19-9 levels were found to be significantly higher and more frequently elevated (24.6 U/mL vs 276.3 U/mL, $p < 0.01$ and 33% vs 88%, $p < 0.01$), and the serum DUPAN-2 levels were more frequently elevated (20% vs 74%, $p < 0.05$) in the patients with hilar CC. On the other hand, the serum IgG and IgG4 levels were

Table 1. Clinical and Laboratory Findings of Immunoglobulin G4-Related Sclerosing Cholangitis (IgG4-SC) and Hilar Cholangiocarcinoma

	IgG4-SC (n=5)	Hilar cholan- giocarcinoma (n=42)	p- value
Male/Female	4/1	23/19	0.377
Age, median	71.0	74.0	0.447
Jaundice, +/-	1/4 (20.0)	32/10 (76.2)	0.023
Abdominal pain, +/-	2/3 (40.0)	8/31 (20.5)	0.317
Median T-bil, mg/dL	0.70	3.75	0.018
Median CA19-9, U/mL	22.6	276.3	0.009
CA19-9 ≥ 37.0 U/mL, +/-	2/3 (40.0)	37/5 (88.1)	0.038
Median CEA, ng/mL	4.4	3.3	0.490
CEA ≥ 5.0 ng/mL, +/-	2/3 (40.0)	12/30 (28.6)	0.991
Median DUPAN-2, U/mL	126.0	733.0	0.069
DUPAN-2 ≥ 150 U/mL, +/-	1/3 (25.0)	29/10 (74.4)	0.140
Median IgG, mg/dL	2,100.0	1,321.5	0.035
IgG $\geq 1,700$ mg/dL, +/-	4/1 (80.0)	2/10 (16.7)	0.028
Median IgG4, mg/dL	903.0	25.7	0.001
IgG4 ≥ 135 mg/dL, +/-	5/0 (100)	1/17 (5.6)	<0.001
Median IgE, IU/mL	298.0	73.6	0.513
IgE ≥ 250 IU/mL, +/-	1/2 (33.3)	1/2 (33.3)	0.386
Autoantibody (ANA/RF), +/-	2/1 (66.7)	2/9 (18.2)	0.354

Data are presented as number (%).

CEA, carcinoembryonic antigen; DUPAN-2, duke pancreatic monoclonal antigen type 2; ANA, antinuclear antibody; RF, rheumatoid factor.

significantly higher and more frequently elevated in the patients with IgG4-SC (2,100.0 mg/dL vs 1,321.5 mg/dL, $p<0.05$ and 83% vs 17%, $p<0.05$) and (873.0 mg/dL vs 25.7 mg/dL, $p<0.01$ and 100% vs 6%, $p<0.01$) (Table 1).

2. Imaging differences

Enlargement of the pancreas as seen on CT and/or MRI was found in all IgG4-SC patients and in 17% of the hilar CC patients ($p<0.01$). Salivary and/or lacrimal gland swelling was detected in only 50% of the IgG4-SC patients ($p<0.01$). There were no differences in the length of stenosis of the hilar bile duct between patients having the two diseases. ERCP revealed that stenosis of the hilar bile duct was delineated in all IgG4-SC patients (Fig. 1), but the hilar or hepatic duct was completely obstructed in 15 of 18 (83%) hilar CC patients ($p<0.01$). Stenosis of the lower bile duct, apart from the hilar bile duct, was more frequent in the patients with IgG4-SC (100% vs 5%, $p<0.01$). Thickening of the bile duct wall in areas without stenosis, as seen on cholangiography, was also more frequent in the IgG4-SC patients (100% vs 12%, $p<0.01$). IDUS showed wall thickness (1.2 to 2.3 mm) with smooth outer margins in the bile ducts without stenosis in the IgG4-SC patients (Fig. 2). There was no

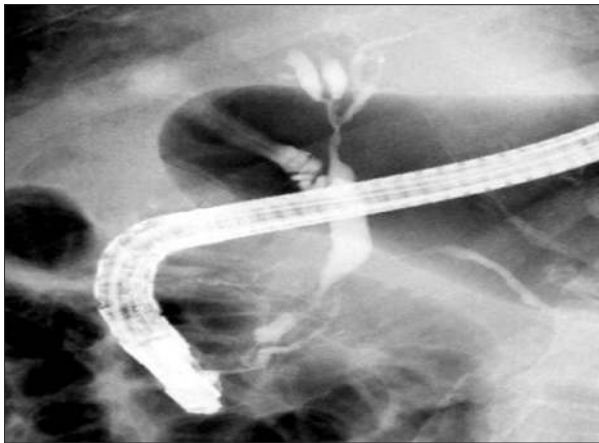


Fig. 1. Endoscopic retrograde cholangiopancreatography shows that stenosis of the hilar bile duct was delineated in immunoglobulin G4-related sclerosing cholangitis patients.

significant difference between patients with IgG4-SC or hilar CC in the incidence of thickening of the gallbladder wall (Table 2).

3. Histological and cytological diagnosis

Bile cytology results were negative in all IgG4-SC patients. Histological diagnosis of bile duct biopsy specimens, based on dense fibrosis with abundant (>10/high power field) infiltration of IgG4-positive plasma cells, was performed in two of five IgG4-SC patients. Bile cytology results were positive in 18 of 28 (64%) patients with hilar CC, and bile duct biopsy was negative in one hilar CC patient.

DISCUSSION

Some benign fibroinflammatory processes at the hilum of the liver have been reported to mimic hilar CC.¹³⁻¹⁶ Approximately 8% to 24% of patients with proximal biliary obstruction presumed to be hilar CC are ultimately proven to have benign strictures on final histological examination.¹³⁻¹⁶ Recently, it has become obvious that some proximal bile duct strictures mimicking hilar CC are caused by IgG4-SC.^{2,3,7-9,16} In a review of 185 patients who underwent major liver resections for presumed

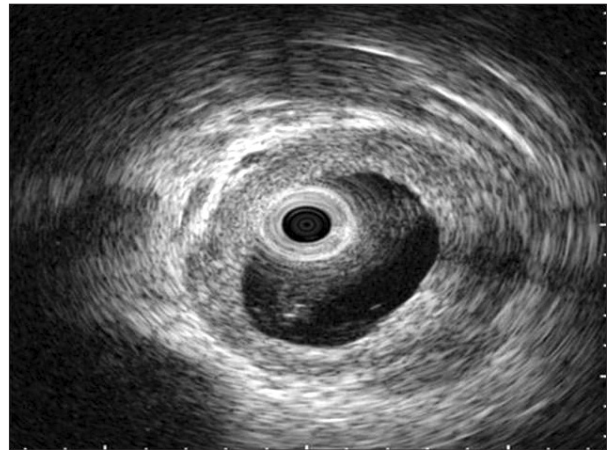


Fig. 2. Intraductal ultrasonography shows wall thickness with smooth outer margins in the bile ducts without stenosis in immunoglobulin G4-related sclerosing cholangitis patients.

Table 2. Radiological Findings of Immunoglobulin G4-Related Sclerosing Cholangitis (IgG4-SC) and Hilar Cholangiocarcinoma

	IgG4-SC (n=5)	Hilar cholangiocarcinoma (n=42)	p-value
Enlargement of pancreas	5/0 (100)	7/35 (16.7)	0.001
Extrapancreatic lesions (lacrimal/salivary gland lesion), +/-	3/2 (60.0)	0/42 (0.0)	0.001
Lymph node swelling	2/3 (40.0)	12/30 (28.6)	0.627
Median length of stenosis of bile duct, mm	25.0	25.0	0.901
Stenosis of lower bile duct (ERCP/MRCP), +/-	5/0 (100)	2/39 (4.9)	<0.001
Thickening of bile duct wall (CT/US), +/-	5/0 (100)	5/37 (11.9)	<0.001
Thickening of gallbladder wall (CT/US), +/-	2/3 (40.0)	11/31 (26.2)	0.607

Data are presented as number (%).

ERCP, endoscopic retrograde cholangiopancreatography; MRCP, magnetic resonance cholangiopancreatography; CT, computed tomography; US, ultrasonography.

hilar CC, Erdogan *et al.*¹⁶ reported that 17% had no evidence of malignancy, and of these, nearly 50% had histologic features consistent with IgG4-SC.

IgG4-SC is a bile duct lesion of IgG4-related systemic disease. Most cases of IgG4-SC are associated with AIP.² Stenosis of the lower bile duct is seen frequently in patients with AIP, but controversy exists as to whether the stenosis is due to IgG4-SC or compression caused by pancreatic inflammatory enlargement.¹⁷ In the revised HISORt criteria, only hilar and/or intrahepatic biliary strictures are recognized as other organ involvement of AIP.¹⁸ In the present study, "IgG4-SC" was the term used to designate IgG4-SC with stenosis of the hilar bile duct, and clinical, serological, and imaging differences were compared between IgG4-SC and hilar CC.

In hilar CC, obstructive jaundice was found to be more frequent, and serum total bilirubin levels were higher. Obstructive jaundice fluctuated during the clinical course of two IgG4-SC patients. ERCP revealed stenosis of the bile duct to be delineated in all IgG4-SC cases, but the bile duct was completely obstructed in 83% of the patients with hilar CC. Given these findings, stenosis of the bile duct appears to be more prominent in hilar CC than in IgG4-SC. Serum CA19-9 levels were significantly higher and more frequently elevated in patients with hilar CC, but two patients with IgG4-SC had elevated serum CA19-9 levels (57.7 and 101 U/mL). According to the report by Hirano *et al.*,¹⁹ serum CA19-9 levels were elevated in five of eight (63%) patients with SC associated with AIP. Thus, serum tumor markers do not seem to help distinguish between IgG4-SC and hilar CC. The present study found that serum IgG4 levels were significantly elevated in all patients with IgG4-SC, but one advanced hilar CC patient had an elevated serum IgG4 level (206 mg/dL). Oseini *et al.*⁹ detected elevation of serum IgG4 levels in 78% of 50 IgG4-SC patients and in 14% of 126 patients with CC. Although these investigators stated that a serum IgG4 level at a cutoff of four times the upper limit of normal (140 mg/dL) is 100% specific for IgG4-SC, the sensitivity for IgG4-SC in their study was only 26%.⁹ Furthermore, two cases of CC associated with IgG4-SC have been reported.^{20,21} Serum IgG4 alone cannot distinguish reliably between IgG4-SC and hilar CC.

Other lesions related to IgG4, such as salivary or lacrimal gland swelling, are important clues for the diagnosis of IgG4-SC. Clinicians should therefore heed the presence of IgG4-related lesions other than pancreatobiliary lesions.

According to a previous study, lower bile duct strictures and segmental or long strictures with prestenotic dilatation are more common in IgG4-SC compared with PSC.^{3,6} In the present study, stenosis of the lower bile duct strongly suggested IgG4-SC, and ERCP detected obstruction of the bile duct only in hilar CC. However, the length of stenosis of the hilar bile duct was not different between the two diseases. Therefore, stenosis located exclusively in the hilar bile duct cannot be differentiated only by cholangiography.

Thickening of the bile duct wall in areas without stenosis, as seen on cholangiography, have been more frequently observed in IgG4-SC patients. According to a study using IDUS, bile duct wall thickness exceeding 0.8 mm in regions of nonstricture determinate by the cholangiogram was highly suggestive of IgG4-SC compared with CC.⁷ In the present study, IDUS showed wall thickness with smooth outer margin in the bile duct without stenosis in IgG4-SC patients. Nakazawa *et al.*²² stated diagnostic criteria for IgG4-SC based on association of AIP or other organ involvement, high serum IgG4, IDUS findings, and pathological findings are useful for distinguishing from pancreatic cancer, PSC, and hilar CC.

Thickening of the gallbladder wall due to IgG4-related sclerosing cholecystitis is a gallbladder lesion of IgG4-related disease.^{23,24} Although significant differences in its incidence have not been seen between the two diseases, marked gallbladder wall thickening suggests IgG4-SC.²⁴

Although transpapillary bile duct biopsy is technically difficult to perform, and biopsy specimens are sometimes small or have artificial degeneration, adequate biopsy specimens are needed for histological diagnosis of IgG4-SC. The diagnostic features of fibrosis with infiltration of IgG4-positive plasma cells are observed in the subepithelial region of the bile duct. Abundant (>10/high power field) infiltration of IgG4-positive plasma cells was reportedly detected in the range of 18%⁷ to 88%⁵ in patients with IgG4-SC. The sensitivity of bile duct biopsy for diagnosing CC has been reported to be 53%²⁵ to 72%⁷. However, abundant infiltration of IgG4-positive plasma cells having been detected in some cases of CC.^{7,8} We consider that IgG4-SC could not be diagnosed only from transpapillary bile duct biopsy with immunostaining of IgG4, although bile duct biopsy is useful for exclusion of CC. Oh *et al.*²⁶ reported that AIP or extrabiliary organ involvement, significant infiltration of IgG4-positive cells, and elevated serum IgG4 levels highly support the diagnosis of IgG4-SC.

We have not undertaken any diagnostic steroid trials for IgG4-SC patients; there is no international consensus regarding this approach. Because the sensitivity of histological and/or cytological diagnosis of hilar CC is relatively lower than that of pancreatic cancer, a steroid trial may be a suitable option when a patient has imaging features suggestive of IgG4-SC, but without elevated serum IgG4-levels or any definite association with AIP, and with negative histological and/or cytological results. However, great caution must be exercised with respect to diagnostic steroid trial. Treating patients suspected of having IgG4-SC with steroids, when the actual underlying condition is hilar CC, may not only delay accurate diagnosis and timely intervention, but may result in fatal outcomes.

One of the limitations of the present study is that the number of IgG4-SC patients was too small for analysis, and IgG4-SC patients without AIP were not included in this study. Another issue was that the diagnostic procedures of ERCP and trans-

papillary biopsy were limited for hilar CC, and IDUS was not performed for hilar CC patients in our hospital. Therefore, additional studies may be necessary to develop a more accurate strategy for differentiating the two diseases.

In summary, elevation of serum IgG and IgG4 levels, IgG4-related involvement of other organs including AIP, stenosis of the lower bile duct, and thickening of the bile duct wall in areas without stenosis are highly suggestive of IgG4-SC. On the other hand, obstructive jaundice, elevation of serum CA19-9 levels, and obstruction of the hilar bile duct as observed on ERCP are more frequent characteristics of hilar CC. An integrated diagnostic approach based on clinical, serological, imaging, and histological findings is necessary to differentiate IgG4-SC from hilar CC.

CONFLICTS OF INTEREST

No potential conflict of interest relevant to this article was reported.

REFERENCES

- Okazaki K, Kawa S, Kamisawa T, et al. Japanese clinical guidelines for autoimmune pancreatitis. *Pancreas* 2009;38:849-866.
- Kamisawa T, Takuma K, Egawa N, Tsuruta K, Sasaki T. Autoimmune pancreatitis and IgG4-related sclerosing disease. *Nat Rev Gastroenterol Hepatol* 2010;7:401-409.
- Nakazawa T, Ando T, Hayashi K, Naitoh I, Ohara H, Joh T. Diagnostic procedures for IgG4-related sclerosing cholangitis. *J Hepatobiliary Pancreat Sci* 2011;18:127-136.
- Kamisawa T, Takuma K, Anjiki H, et al. Sclerosing cholangitis associated with autoimmune pancreatitis differs from primary sclerosing cholangitis. *World J Gastroenterol* 2009;15:2357-2360.
- Ghazale A, Chari ST, Zhang L, et al. Immunoglobulin G4-associated cholangitis: clinical profile and response to therapy. *Gastroenterology* 2008;134:706-715.
- Nakazawa T, Ohara H, Sano H, et al. Cholangiography can discriminate sclerosing cholangitis with autoimmune pancreatitis from primary sclerosing cholangitis. *Gastrointest Endosc* 2004;60:937-944.
- Naitoh I, Nakazawa T, Ohara H, et al. Endoscopic transpapillary intraductal ultrasonography and biopsy in the diagnosis of IgG4-related sclerosing cholangitis. *J Gastroenterol* 2009;44:1147-1155.
- Kawakami H, Zen Y, Kuwatani M, et al. IgG4-related sclerosing cholangitis and autoimmune pancreatitis: histological assessment of biopsies from Vater's ampulla and the bile duct. *J Gastroenterol Hepatol* 2010;25:1648-1655.
- Oseini AM, Chaiteerakij R, Shire AM, et al. Utility of serum immunoglobulin G4 in distinguishing immunoglobulin G4-associated cholangitis from cholangiocarcinoma. *Hepatology* 2011;54:940-948.
- Hamano H, Kawa S, Uehara T, et al. Immunoglobulin G4-related lymphoplasmacytic sclerosing cholangitis that mimics infiltrating hilar cholangiocarcinoma: part of a spectrum of autoimmune pancreatitis? *Gastrointest Endosc* 2005;62:152-157.
- Shimosegawa T, Chari ST, Frulloni L, et al. International consensus diagnostic criteria for autoimmune pancreatitis: guidelines of the International Association of Pancreatology. *Pancreas* 2011;40:352-358.
- Haaga JR, Alfydi RJ, Zelch MG, et al. Computed tomography of the pancreas. *Radiology* 1976;120:589-595.
- Gerhards MF, Vos P, van Gulik TM, Rauws EA, Bosma A, Gouma DJ. Incidence of benign lesions in patients resected for suspicious hilar obstruction. *Br J Surg* 2001;88:48-51.
- Koea J, Holden A, Chau K, McCall J. Differential diagnosis of stenosing lesions at the hepatic hilus. *World J Surg* 2004;28:466-470.
- Corvera CU, Blumgart LH, Darvishian F, et al. Clinical and pathologic features of proximal biliary strictures masquerading as hilar cholangiocarcinoma. *J Am Coll Surg* 2005;201:862-869.
- Erdogan D, Kloek JJ, ten Kate FJ, et al. Immunoglobulin G4-related sclerosing cholangitis in patients resected for presumed malignant bile duct strictures. *Br J Surg* 2008;95:727-734.
- Hirano K, Tada M, Isayama H, et al. Endoscopic evaluation of factors contributing to intrapancreatic biliary stricture in autoimmune pancreatitis. *Gastrointest Endosc* 2010;71:85-90.
- Chari ST, Takahashi N, Levy MJ, et al. A diagnostic strategy to distinguish autoimmune pancreatitis from pancreatic cancer. *Clin Gastroenterol Hepatol* 2009;7:1097-1103.
- Hirano K, Shiratori Y, Komatsu Y, et al. Involvement of the biliary system in autoimmune pancreatitis: a follow-up study. *Clin Gastroenterol Hepatol* 2003;1:453-464.
- Oh HC, Kim JG, Kim JW, et al. Early bile duct cancer in a background of sclerosing cholangitis and autoimmune pancreatitis. *Intern Med* 2008;47:2025-2028.
- Straub BK, Esposito I, Gotthardt D, et al. IgG4-associated cholangitis with cholangiocarcinoma. *Virchows Arch* 2011;458:761-765.
- Nakazawa T, Naitoh I, Hayashi K, et al. Diagnostic criteria for IgG4-related sclerosing cholangitis based on cholangiographic classification. *J Gastroenterol* 2012;47:79-87.
- Kamisawa T, Tu Y, Nakajima H, et al. Sclerosing cholecystitis associated with autoimmune pancreatitis. *World J Gastroenterol* 2006;12:3736-3739.
- Leise MD, Smyrk TC, Takahashi N, Sweetser SR, Vege SS, Chari ST. IgG4-associated cholecystitis: another clue in the diagnosis of autoimmune pancreatitis. *Dig Dis Sci* 2011;56:1290-1294.
- Weber A, von Weyhern C, Fend F, et al. Endoscopic transpapillary brush cytology and forceps biopsy in patients with hilar cholangiocarcinoma. *World J Gastroenterol* 2008;14:1097-1101.
- Oh HC, Kim MH, Lee KT, et al. Clinical clues to suspicion of IgG4-associated sclerosing cholangitis disguised as primary sclerosing cholangitis or hilar cholangiocarcinoma. *J Gastroenterol Hepatol* 2010;25:1831-1837.