

Liver resection for metastatic soft tissue sarcoma: An analysis of prognostic factors[☆]

R. Marudanayagam^{*}, B. Sandhu, M.T.P.R. Perera, S.R. Bramhall, D. Mayer,
J.A.C. Buckels, D.F. Mirza

*Department of Hepatobiliary and Transplantation Surgery, Liver Unit, Queen Elizabeth Hospital,
University Hospital of Birmingham NHS Foundation Trust, Birmingham B15 2TH, UK*

Accepted 4 November 2010

Abstract

Aim: The aim of this retrospective study was to analyse the outcome following hepatic resection for metastatic STS and to identify factors predicting survival.

Methods: All patients who underwent hepatic resection for metastatic STS between August 1997 and April 2009 were included. The data was obtained from a prospectively maintained database. Patients' demographics, clinico-pathological parameters, overall survival and the factors predicting survival were analysed.

Results: Thirty-six patients underwent hepatic resection for metastasis, with a median age of 58 years. The predominant site of primary tumour was the gastro-intestinal tract (50%). Leiomyosarcoma was the most common histological type (54%). The median interval between the primary and metastatic resections was 17 months. Thirteen patients had synchronous tumours. 24 patients had major liver resections and 10 patients had bi-lobar disease. The median number of liver lesions resected was 1(1–6) and the median maximum diameter was 11 cm (1–26 cm). R0 resection was performed in 31 patients. The 1-, 3- and 5-year overall survival from the time of metastasectomy was 90.3%, 48.0% and 31.8% respectively, with a median survival of 24 months. Factors associated with poor survival on univariate analysis were the presence of high grade tumours ($p = 0.04$), primary leiomyosarcoma ($p = 0.01$) and positive resection margin of liver metastasis ($p = 0.04$), whilst multivariate analysis predicted primary leiomyosarcoma as a risk factor for poor survival ($p = 0.01$).

Conclusion: Hepatic resection for metastatic STS appears to be valuable in carefully selected patients with acceptable long-term survival. The aim of surgery must be an R0 resection to offer a chance of cure.

© 2010 Elsevier Ltd. All rights reserved.

Keywords: Hepatic resection; Metastatic sarcoma; Soft tissue sarcoma; Leiomyosarcoma

Introduction

Soft tissue sarcomas (STS) are a heterogenous group of tumours with propensity for haematogenous spread. 25–40% of all patients with STS develop distant metastasis, despite adequate local disease control.¹ Liver is the predominant site of metastasis from abdominal and pelvic sarcomas. Hepatic metastasis is reported to occur in 20–60% of patients with visceral or retroperitoneal sarcomas.^{2–5}

The reported median survival of untreated patients with liver metastasis from STS was no more than 14 months.^{3,6} With the exception of gastro-intestinal stromal tumours (GIST), the response rates following systemic chemotherapy are poor, with limited duration of response.^{7,8} Similarly the role of chemoembolisation is limited with a median duration of regression of 12 months.⁹ Radiofrequency ablation (RFA) alone was associated with a median survival of 25 months in a selected group of patients with STS.¹⁰ However, this was limited by a number of factors including tumour size and proximity to vessels.¹¹

Hepatic resection has become an accepted form of treatment for patients with colorectal and neuro-endocrine metastasis, with a mortality of <5% in specialized centres.¹²

[☆] Paper presented as e-poster of distinction at the Association of Surgeons of Great Britain and Ireland (ASGBI), Liverpool, April 2010.

^{*} Corresponding author. Tel.: +44 7816457854; fax: +44 121 5441529.
E-mail address: ravim1973@yahoo.co.in (R. Marudanayagam).

In patients with STS, surgical resection appears justified in view of the poor response to other therapeutic options available. However, the role of hepatic resection for metastatic STS is poorly defined. The purpose of this study was to analyse the outcome following liver resection for metastatic STS and to identify factors that predict survival.

Patients and methods

All the patients who underwent hepatic resection for STS between August 1997 and April 2009 at the University Hospital of Birmingham NHS Trust were included in the study. The data was obtained from the prospectively maintained hospital based liver unit and pathology database. The study was approved by the Clinical and Audit Governance unit of the trust.

Selection criteria

Hepatic resection was considered if the lesions were technically resectable with adequate residual hepatic functional reserve, in patients where adequate primary local disease control could be achieved. Hepatic functional reserve was evaluated by a combination of pre-operative imaging and liver function tests. All the patients were assessed at the multi-disciplinary meeting involving surgeons, oncologists, radiologists and pathologists. The presence of resectable extra-hepatic disease did not preclude hepatic resection. Patients with primary hepatic sarcoma and primary STS infiltrating into the liver were excluded from the study.

Post-operatively patients were followed-up clinically and radiologically every 3 months for the first year, every 4 months for the second year, every 6 months for the third year and yearly thereafter till the fifth post-operative year. Radiological imaging consisted of computerized tomographic scan of the chest, abdomen and pelvis with contrast and/or magnetic resonance imaging of the abdomen.

Parameters studied

The parameters studied were patient demographics, operative parameters and clinico-pathological characteristics. The clinical parameters analysed were the site of primary tumour (gastro-intestinal vs. other tumours), timing of presentation of liver lesions (synchronous vs. metachronous), and the time interval between the surgery for primary sarcoma and liver resection (≤ 24 months vs. > 24 months). Synchronous liver metastasis was defined as the presence of simultaneous liver lesion and primary tumour or the development of hepatic metastasis within 3 months of resection of primary tumour. The operative parameters studied were the type of liver resection (resection of > 3 segments vs. ≤ 3 segments) and the presence or absence of extra-hepatic disease. Pathological parameters included the histology of primary tumour (leiomyosarcoma vs. other sarcoma types), number of liver lesions (solitary vs. > 1

lesion), maximum diameter of the liver tumour based on median tumour size (> 11 cm vs. ≤ 11 cm), unilobar vs. bi-lobar disease, grade of tumour (high grade vs. others) and the resection margin status (involved margin vs. tumour free margin). For the purpose of analysis, the Trajoni grade 1, 2 and 3 for sarcoma were categorized as low, intermediate and high grade respectively. For sarcomatoid renal cell tumours, Fuhrman grade 1–4 was followed. Fuhrman grade 1 was considered as low grade, 2 and 3 were grouped as intermediate grade and 4 as high grade tumour. All sarcomatoid renal cell tumours had more than 85% mesenchymal component.

The above-mentioned parameters were further analysed to identify their influence on predicting outcome following liver resection. The overall 1-, 3- and 5-year survival was calculated from the time of hepatic metastasectomy.

Statistical analysis

Data on above mentioned parameters were entered as binary variables. String and nominal data in the studied variables were re-categorized into binary variables based on their distribution across the median. The outcome end point assessed was mortality. Univariate significance of the each mentioned variable was assessed with “cross tabulation” using the Chi Square test or Fisher’s exact test.

A multivariate analysis model was designed employing binary regression analysis. Given the smaller sample size, hence smaller number of events (mortality), only the variables that predicted significant association with mortality on the univariate analysis were entered to this multivariate model. Actuarial survival was analysed using the Kaplan–Meier method. Statistical analysis was performed using SPSS for windows software (version 17; Chicago, Illinois, USA). The level of significance was set at $p < 0.05$ at 95% confidence interval.

Results

A total of 36 patients underwent hepatic resection for metastatic STS between August 1997 and April 2009. The median age at the time of presentation of hepatic metastasis was 58 years (range: 23–81 years). There were 13 men and 23 women.

The most common site of primary tumour was gastro-intestinal tract seen in 18 patients. This included stomach (6 patients), mesentery (6 patients), small bowel (5 patients) and colon (1 patient). Fig. 1 shows the site of primary tumour in all 36 patients. The predominant histological subtype of primary tumour was leiomyosarcoma, seen in 20 patients, followed by GIST in five patients (Fig. 2). Thirteen patients had synchronous liver metastasis, while the remaining 23 patients had metachronous liver tumours. The median time interval between surgery for primary tumour and liver resection was 17 months, ranging from zero to 322 months.

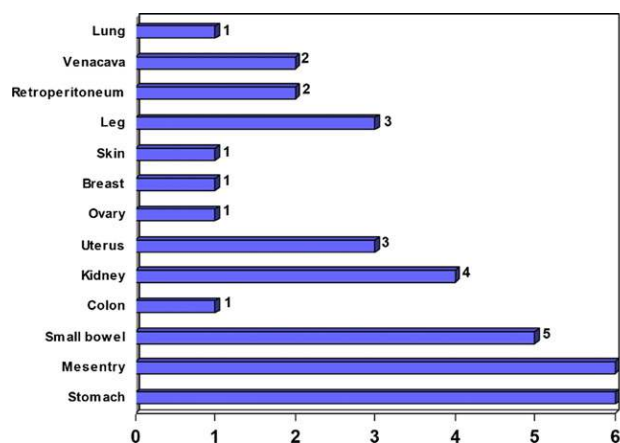


Figure 1. Site of primary tumour.

All of the 5 patients with GIST had resectable liver metastasis at the time of presentation. Hence liver resection was offered as the primary treatment. None of them received adjuvant imatinib mesylate, as these patients were all treated prior to the published evidence.

Hepatic resection

The different types of liver resections performed are summarized in Fig. 3. Right hepatectomy or an extended right hepatectomy with or without a non-anatomical resection was the most commonly undertaken procedure (18 patients). Major liver resection, defined as removal of three or more couinau’s segments, was performed in 24 patients. Bilobar disease was present in 10 patients.

Histological examination of the resected specimen revealed the median number of liver lesions to be one, varying from 1 to 6. Solitary liver metastasis was seen in 27 patients, 2 lesions in 6 patients and 3, 4 and 5 lesions in 1 patient each. The median maximum diameter of the resected liver lesion was 11 cm (range: 1–26 cm).

Complete resection of the liver tumour with negative microscopic surgical margins (R0 resection) was achieved in 31 patients, while the remaining 5 patients had microscopic involvement of one of the resection margins (R1 resection).

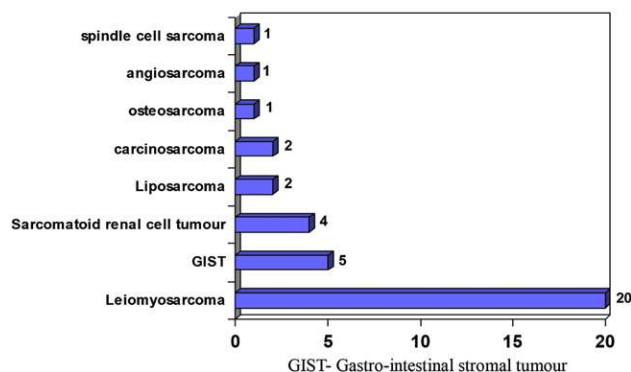
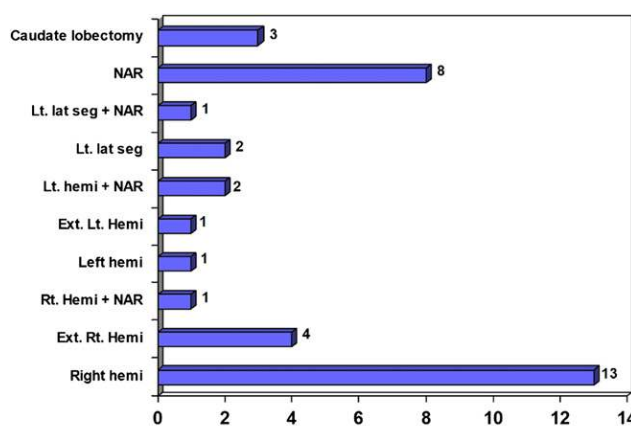


Figure 2. Histology of primary tumour.



NAR- Non-anatomical resection
 Lt. lat seg- Left lateral segmentectomy
 Lt. hemi- Left hemihepatectomy
 Ext. Lt. Hemi- Extended left hepatectomy
 Rt. Hemi- Right hemihepatectomy
 Ext. Rt. Hemi- Extended right hepatectomy

Figure 3. Type of liver resections performed.

None of the patients had R2 resection, defined as gross residual tumour after resection. Tumour grading revealed the presence of high grade tumor in 19 patients, intermediate grade tumour in 12 patients and low grade tumour in 5 patients.

Extra-hepatic disease

Resectable extra-hepatic disease at the time of liver resection was seen in 11 patients. The sites of extra-hepatic disease were pancreas (2 patients), peri-pancreatic nodule (1 patient), omental nodule (1 patient), diaphragm (1 patient), small bowel and peritoneal nodule (1 patient), diaphragm and left lung lower lobe (1 patient), gallbladder (1 patient), adrenal and diaphragm (1 patient), stomach (1 patient), chest nodule, colon and adrenal (1 patient). All the patients with extra-hepatic disease had an R0 resection.

Multiple resections

Two patients had multiple resectional procedures for metastasis outside the liver, prior to liver resection. One of these patients had an omental nodule excision for metastasis one year after surgery for primary uterine carcinosarcoma, followed by liver resection 6 years later. The second patient had an en-bloc resection of distal pancreas, left kidney, adrenal and spleen three years following excision of primary retroperitoneal sarcoma. This was followed by resection of small bowel and gallbladder 19 years later, subsequently followed by liver resection four years later.

One patient had a repeat liver resection for tumour recurrence within the liver. This patient had a left hemi-

hepatectomy and a non-anatomical resection of a segment 6 lesion 2 years after the surgery for primary gastric leiomyosarcoma. Subsequently another wedge liver resection was performed for recurrence 3 years later.

Survival data

The median follow up was 24 months. Survival was calculated from the time of hepatic resection for metastasis and the primary end point was death. The median overall survival was 24 months, ranging from two to 141 months. The actuarial overall survival following hepatic metastasectomy for STS was 90.3% at 1 year, 48% at 3 years and 31.8% at 5 years. There was no 30-day mortality and the 90-day mortality was 8.3%.

Prognostic factors

A number of prognostic factors were analysed to identify their impact on survival. These included presence of synchronous lesions, interval between surgery for primary tumour and liver resection, site and histological type of primary tumour, type of liver resection, presence of bi-lobar disease, number and size of liver lesions, grade of tumour, status of resection margins and the presence of extra-hepatic disease. Among all these parameters, the factors that were associated with poor survival outcome on univariate analysis were the presence of leiomyosarcoma ($p = 0.01$), high grade tumour ($p = 0.04$) and microscopic positive resection margin of liver metastasis ($p = 0.04$) (Table 1). All of the other factors including the presence of synchronous liver lesions, number of liver lesions and the presence of resectable extra-hepatic disease did not have any influence on survival (Table 1). The role of chemotherapy was not studied due to the heterogeneous nature of the tumour types.

These negative predictive factors recognized on univariate analysis were further individually analysed to identify their impact on 5-year survival. The 5-year survival following resection for a primary leiomyosarcoma was 25%

compared with 50% for a non-leiomyosarcomatous tumour. Similarly, high grade tumours had a 5-year survival of 7.1% in contrast to 75% for a low or intermediate grade tumour. The 5-year survival dropped from 35.3% after an R0 resection, to 20% after an R1 resection.

In the binary logistic regression model, only these three variables that were shown to be associated with mortality were tested with “forward stepwise enter” method. With only 20 cases of death during the follow up, each variable studied had approximately seven events per variable (EPV) thereby reducing the chance of type I error despite small sample size. The final model static for the multivariate analysis was 0.008 denoting the significance of the model employed. This multivariate model predicted only leiomyosarcoma ($P = 0.01$) as an independent predictor of poor survival following hepatic resection for STS. The results of multivariate analysis are shown in Table 2.

Discussion

The therapeutic options for patients with metastasis from STS include systemic chemotherapy, chemoembolisation, radiofrequency ablation, partial hepatectomy and liver transplantation. Systemic chemotherapy in general does not provide a survival benefit in metastatic sarcomas.^{13–15} Studies have shown that chemotherapy with ifosfamide, mitomycin and doxorubicin regimens for liver metastasis from leiomyosarcoma have very poor response rates, with the duration of response lasting only a few weeks to months.^{7,8} Chemoembolisation could theoretically be effective, as these metastases are mostly hypervascular. Mavligit et al studied the effect of embolisation with polyvinyl alcohol sponge particles mixed with cisplatin, followed by intra-arterial infusion of vinblastine in 14 patients. The reported response rate was 70% with more than 50% regression. However, the median duration of regression was only 12 months.⁹ Pawlik et al studied the effect of RFA on metastatic sarcoma to the liver and concluded that treatment with RFA either alone or in combination with resection predicted shorter disease free survival.¹⁶ There are only anecdotal reports on the role of liver transplantation for metastatic sarcoma. The Pittsburgh group performed upper abdominal exenteration and cluster transplantation for metastatic stromal tumours and reported a high recurrence rate of 83%.^{17,18}

Table 1
Univariate analysis of prognostic factors.

| Risk Factors | P-value |
|--|-------------------|
| Synchronous vs. metachronous lesions | 0.48 |
| Interval between surgery for primary tumour and liver resection: ≤ 24 vs. > 24 months | 0.32 |
| Primary GI tumour vs. other tumours | 0.74 |
| Leiomyosarcoma vs. other tumours | 0.01 ^a |
| Resection > 3 vs. ≤ 3 segments | 0.08 |
| Bi-lobar vs. unilobar disease | 0.13 |
| No. of lesions: solitary vs. > 1 | 0.70 |
| Max. diameter: > 11 cm vs. ≤ 11 cm | 0.74 |
| High grade tumour vs. other grades | 0.04 ^a |
| Involved margin (R1) vs. free margin (R0) | 0.04 ^a |
| Extra-hepatic disease: presence vs. absence | 1.00 |

^a Statistically significant cross tabulation; Chi Squared test.

Table 2
Binary logistic regression model: Forward stepwise (Wald) method, model statistic, $p = 0.008$.

| Variable | Hazard ratio (95% Confidence Interval) | DF | Multivariate Significance |
|--------------------------------|--|----|---------------------------|
| Leiomyosarcoma | 6.39 (4.9–8.8) | 1 | 0.01 ^a |
| High grade tumours | 3.40 (0.92–5.88) | 1 | 0.06 |
| Resection margin involved (R1) | 3.55 (0.87–6.33) | 1 | 0.05 |

^a Statistically significant.

The reasons to adopt hepatic resection for metastatic sarcoma are many-fold. Studies have shown that resection of pulmonary metastasis from sarcoma is possible and is associated with a 5-year survival of 15%.¹⁹ Moreover, for patients with liver metastasis, there is no efficient alternative therapy and hepatic resection could safely be performed with a peri-operative mortality of <5% in most specialized centres.¹²

Survival data

In the present series, the overall 1-, 3- and 5-year survival was 90.3%, 48% and 31.8% respectively. This correlates with the results of the largest series on metastatic sarcoma published so far. DeMatteo et al from the Memorial Sloan-Kettering group studied the outcome of hepatic resection for metastatic sarcoma in 56 patients and reported a 1-, 3- and 5-year survival of 88%, 50% and 30% respectively.²⁰ Similarly, Pawlik et al reported an overall 5-year survival of 27%.¹⁶ Although their study included 66 patients, only 35 patients had hepatic resection alone and a further 18 patients underwent resection and RFA. Also, in this study patients with GIST received adjuvant imatinib mesylate. In a recent study published by Rehders et al., the reported 5-year survival of the 27 patients who underwent resection was 33%, calculated from the time of metastasectomy.²¹ This high 5-year survival was believed to be related to the highly favourable patient selection and the fact that most of the tumours were low grade leiomyosarcomas. In the current study, the good overall survival could be attributed to the selection of patients with favourable tumour biology and a high rate of R0 resection (86%).

Prognostic factors

Controversy still exists regarding the prognostic factors that predict survival after liver resection. The present study demonstrated that the overall survival was improved if the histology of the primary tumour was non-leiomyosarcoma, the tumour was of low/intermediate grade and the microscopic resection margin was clear of tumour. None of the other studies have identified these factors as predictors of survival.^{16,20–24} DeMatteo et al. identified three factors which predicted favourable survival on univariate analysis: disease free interval (DFI) of more than 2 years, major liver resection and the presence of metachronous metastasis defined as the development of liver metastasis more than 6 months after the onset of primary tumour.²⁰ However, on multivariate analysis, DFI of more than 2 years was the only predictor of outcome. This was reconfirmed in the recent publication of Rehders et al.²² Pawlik et al concluded that patients who were treated with adjuvant chemotherapy had a longer median overall survival compared with those who underwent surgery alone.¹⁶ More specifically, patients with GIST who received adjuvant imatinib mesylate had the longest median survival.

Interestingly in the present study, the presence of resectable extra-hepatic disease did not influence outcome. This is possibly because all these patients had a complete R0 resection. Moreover, all but one patient had the extra-hepatic disease in the abdominal cavity. This was confirmed in the study by Lang et al.²¹ They concluded that the presence of extra-hepatic disease should be considered a contraindication for liver resection only if an R0 resection could not be achieved. Ng et al reported that extra-hepatic intra-abdominal metastasis carries a better prognosis than an extra-abdominal metastasis.³

Recurrent disease

In the present series, three patients developed recurrent disease, of whom one had recurrence within the liver. All of these patients were treated by repeat surgical resections. This recurrence rate is significantly lower compared with the published data, which ranges from 59.3% to 94%.^{16,20,22,24} In all of these studies the liver was found to be the most common site of recurrent disease, ranging from 43.7% to 88%. This significant disparity in the recurrence rate between the current series and the other studies could be explained by the fact that 86% of our patients had an R0 resection, although none of them had any form of adjuvant therapy. Rehders et al have demonstrated that patients treated conservatively for recurrent disease had a significantly worse outcome compared with those who had repeat resections.²² Lang et al found that despite good results following repeat liver resections for recurrent metastasis, there was not a single 5-year survivor and all of the patients died of disseminated disease.²¹ They therefore concluded that there is no possible chance of cure in this group of patients with multiple recurrent diseases, as this represents systemic spread rather than isolated intra-hepatic disease.

Limitations

The limitations of this study are the presence of a heterogeneous group of patients with different histological subtypes, the small patient population and the retrospective nature of the study, although the data were collected prospectively. The heterogeneous nature of the study population makes it difficult to interpret the outcome, as each histological subtype behaves differently. However, it is not possible to compare the results between different histological groups, as the number of patients in each subgroup is small. The other drawback is that the patients included in the study are likely to be a selected group with highly favourable tumour biology and may not represent the general population of patients with sarcoma metastasis. Despite these limitations, the study does suggest a favourable outcome in patients who have had an R0 resection.

Conclusion

We conclude that hepatic resection for metastatic STS appear to be valuable in carefully selected patients with

an acceptable long-term survival. The study demonstrated that the presence of a high grade tumour, a primary leiomyosarcoma and a microscopic positive resection margin are associated with a poor survival. Hence the aim of surgery must be an R0 resection to offer a chance of cure. Surgery may not be considered as the first modality of treatment for patients with high grade tumour as it is associated with a very poor outcome. The presence of extra-hepatic disease should not be considered a contraindication to resection, if an R0 resection can be achieved. However, large multicentre studies are required to verify the results.

Conflict of interest statement

No conflict of interest.

Funding

No funding utilized.

Acknowledgement

We would like to acknowledge Dr. Phillippe Taniere, Consultant Pathologist and Mr. Chris Coldham, Data manager, Queen Elizabeth Hospital, Birmingham, U.K for their help in the collection of data.

References

- Pisters PW, Leung DH, Woodruff J, Shi W, Brennan MF. Analysis of prognostic factors in 1041 patients with localized soft tissue sarcomas of the extremities. *J Clin Oncol* 1996;**14**:1679–89.
- Mudan SS, Conlon KC, Woodruff JM, Lewis JJ, Brennan MF. Salvage surgery for patients with recurrent gastrointestinal sarcoma: prognostic factors to guide patient selection. *Cancer* 2000;**88**:66–74.
- Ng EH, Pollock RE, Romsdahl MM. Prognostic implications of patterns of failure for gastrointestinal leiomyosarcomas. *Cancer* 1992;**69**:1334–41.
- DeMatteo RP, Lewis JJ, Leung D, Mudan SS, Woodruff JM, Brennan MF. Two hundred gastrointestinal stromal tumours: recurrence patterns and prognostic factors for survival. *Ann Surg* 2000;**231**:51–8.
- Jaques DP, Coit DG, Casper ES, Brennan MF. Hepatic metastases from soft tissue sarcoma. *Ann Surg* 1995;**221**:392–7.
- Jaffe BM, Donegan WL, Watson F, Spratt JS. Factors influencing survival in patients with untreated hepatic metastases. *Surg Gynecol Obstet* 1968;**127**:1–11.
- Edmonson JH, Ryan LM, Blum RH, et al. Randomised comparison of doxorubicin alone versus ifosfamide or mitomycin, doxorubicin and cisplatin against advanced soft tissue sarcomas. *J Clin Oncol* 1993;**11**:1269–75.
- Casper ES, Christman KL, Schwartz GK, Johnson B, Brennan MF, Bertino JR. Edatrexate in patients with soft tissue sarcoma: activity in malignant fibrous histiocytoma. *Cancer* 1993;**72**:766–70.
- Mavligit GM, Zukwiski AA, Ellis LM, Chuang VP, Wallace S. Gastrointestinal leiomyosarcoma metastatic to the liver: durable tumour regression by hepatic chemoembolisation infusion with cisplatin and vinblastine. *Cancer* 1995;**95**:2083–8.
- Berber E, Ari E, Herceg N, Siperstein A. Laparoscopic radiofrequency thermal ablation for unusual hepatic tumours: operative indications and outcomes. *Surg Endosc* 2005;**19**:1613–7.
- Mulier S, Ni Y, Jamart J, Ruers T, Marchal G, Michel L. Local recurrence after hepatic radiofrequency coagulation: multivariate meta-analysis and review of contributing factors. *Ann Surg* 2005;**242**:158–71.
- Scheele J, Stang R, Altendorf-Hofmann A, Paul M. Resection of colorectal liver metastases. *World J Surg* 1995;**19**:59–71.
- Sarcoma Meta-analysis Collaboration. Adjuvant chemotherapy for localized resectable soft-tissue sarcoma of adults: meta-analysis of individual data. *Lancet* 1997;**350**:1647–54.
- Van Glabbeke M, Van Oosterom AT, Oosterhuis JW, et al. Prognostic factors for the outcome of chemotherapy in advanced soft tissue sarcoma: an analysis of 2185 patients treated with anthracycline-containing first line regimens – a European Organization for Research and Treatment of Cancer Soft Tissue and Bone Sarcoma Group Study. *J Clin Oncol* 1999;**17**:150–7.
- Le Cesne A, Judson I, Crowther D, et al. Randomised phase 3 study comparing conventional-dose doxorubicin plus ifosfamide versus high-dose doxorubicin plus ifosfamide plus recombinant human granulocyte-macrophage colony-stimulating factor in advanced soft tissue sarcomas: a trial of the European Organization for Research and Treatment of Cancer Soft Tissue and Bone Sarcoma Group. *J Clin Oncol* 2000;**18**:2676–84.
- Pawlik TM, Vauthey JN, Abdalla EK, Pollock RE, Ellis LM, Curley SA. Results of a single-center experience with resection and ablation for sarcoma metastatic to the liver. *Arch Surg* 2006;**141**:537–44.
- Alessiani M, Tzakis A, Todo S, Demetris AJ, Fung JJ, Starzi TE. Assessment of five-year experience with abdominal organ cluster transplantation. *J Am Coll Surg* 1995;**180**:1–9.
- Iwatsuki S, Tzakis A, Todo S, Selby R, Starzl TE. Liver transplantation for metastatic hepatic malignancies. *Hepatology* 1993;**18**:723.
- Billingsley KG, Burt ME, Jara E, et al. Pulmonary metastases from soft tissue sarcoma: analysis of patterns of diseases and postmetastasis survival. *Ann Surg* 1999;**229**:602–10.
- DeMatteo RP, Shah A, Fong Y, Jarnagin WR, Blumgart LH, Brennan MF. Results of hepatic resection for sarcoma metastatic to liver. *Ann Surg* 2001;**234**(4):540–8.
- Lang H, Nussbaum K, Kaudel P, Fruhauf N, Flemming P, Raab R. Hepatic metastases from leiomyosarcoma: a single-centre experience with 34 liver resections during a 15-year period. *Ann Surg* 2000;**231**(4):500–5.
- Rehders A, Peiper M, Stoecklein NH, et al. Hepatic metastasectomy for soft-tissue sarcomas: is it justified? *World J Surg* 2009;**33**:111–7.
- Gomez D, Al-Mukthar A, Menon KV, Toogood GJ, Lodge JPA, Prasad KR. Aggressive surgical resection for the management of hepatic metastases from gastrointestinal stromal tumours: a single centre experience. *HPB* 2007;**9**:64–70.
- Nunobe S, Sano T, Shimada K, Sakamoto Y, Kosuge T. Surgery including liver resection for metastatic gastrointestinal stromal tumours or gastrointestinal leiomyosarcomas. *Jpn J Clin Oncol* 2005;**35**(6):338–41.